

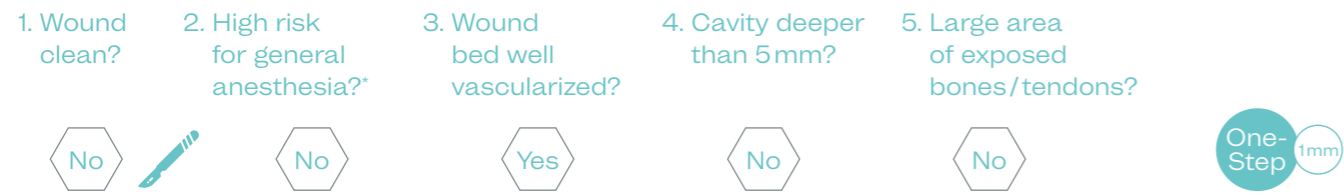
Pediatric scald burn

Type of Wound Scald burn on the foot*

Etiology Burn wound

Patient 2-year-old child

Decision Tree

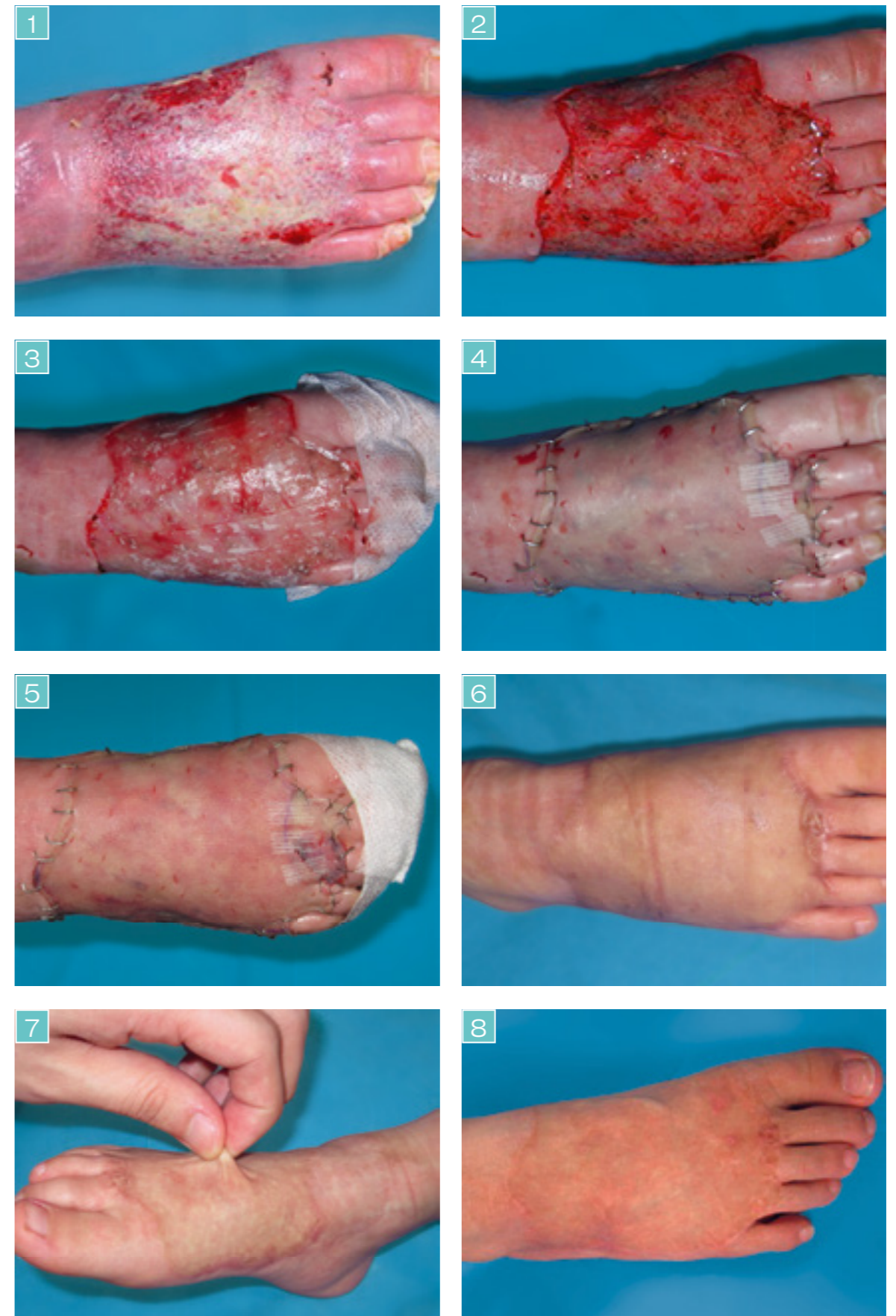

A 2-year-old child presented with a scald burn on the right foot (Fig.1). At the subsequent surgery the wound was carefully debrided (Fig.2). Due to the higher risk of contracture because of the young age of the patient, it was decided to use MatriDerm® in an attempt to prevent scar tissue formation and contracture.

MatriDerm® was applied to the wound bed and trimmed appropriately (Fig.3). A split-thickness skin graft (STSG) was placed on top of MatriDerm® in a One-Step Procedure (Fig.4). The STSG was secured using staples.

At 2 days follow-up the wound showed good signs of healing and good take rate of the graft (Fig.5). At 6 months the wound was completely healed without scarring (Fig.6). At 1 year follow-up the skin demonstrated excellent pliability and good aesthetic result (Fig.7). At 4 year follow-up the grafted area showed same skin color as the surrounding skin (Fig.8). The regenerated skin is growing at the same rate as the surrounding tissue.

This case demonstrates that MatriDerm® can be used successfully in pediatric patients with excellent aesthetic and functional outcomes.



* Courtesy of J. Lee, MD, Seoul, S. Korea